KEM.

What has happened in the last 2 years in gender surgery?

Prof. Dr.med. Susanne Krege
Klinik für Urologie, Kliniken Essen Mitte

no conflicts of interest

Gender surgery – a panorama of procedures

KEM.

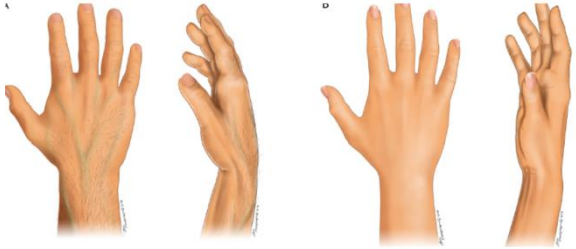



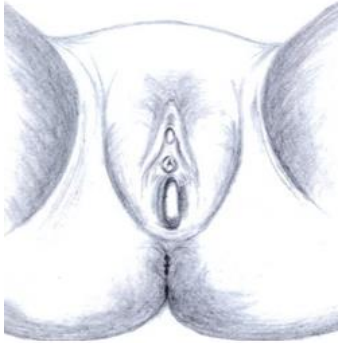

German guideline – Gender reassignment surgical procedures in case of gender-dysphoria

KEM.

systematic literature search and interdisciplinary consensus process

definition of the topic

surgical procedures – indications/ contraindications, informed consent, pre- and postoperative management,
procedures
complications/trouble shooting
follow-up, outcomes/ patients‘ satisfaction

genital surgery
chest and breast surgery
facial surgery
larynx and vocal cord surgery
epilation

gender reassignment in adolescents
reverse surgery
non binarity
fertility
sexuality

German guideline – Gender reassignment surgical procedures in case of gender-dysphoria

KEM.

Coordination by the German Association of Urology and German Association of Plastic Reconstructive and Aesthetic Surgeons

supervised by

Dr. med Julia Bohr

Dpt. of Urology
Kliniken Essen Mitte

Prof. Dr. med Jochen Hess

Dpt. of Urology
University of Essen

MtF-alignment: penile inversion technique

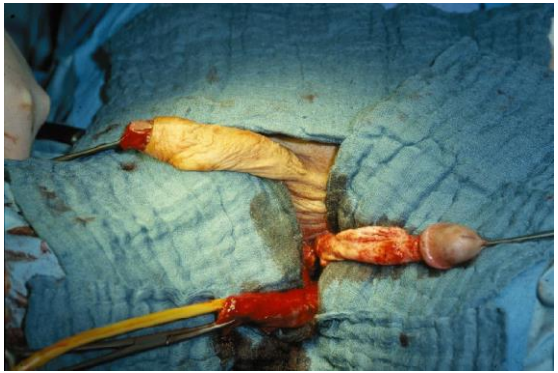

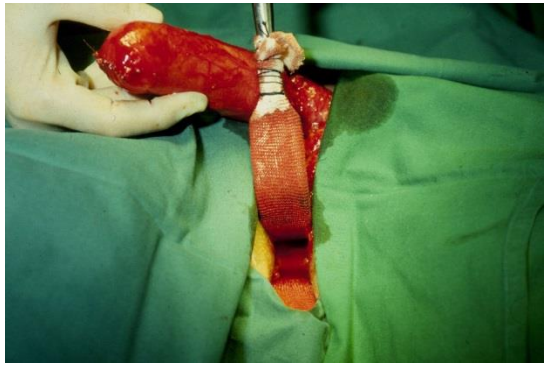

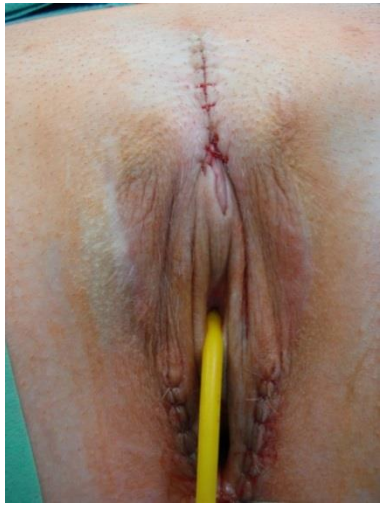

Variation with urethral mucosa lining

Variation with creation of labia minora by the foreskin

MtF-alignment
using nile Tilapia Fish skin as a biocompatible graft

KEM.

inversion of the penile skin augmented with the hollow Nile tilapia skin mold, filling in an inflatable mold for 7 days, then use of progressively larger dilators

Rodriguez AH et al. doi.org/10.1016/j.jmig.2020.02.017

Robotic Davydov peritoneal flap vaginoplasty for vaginal depth in feminizing vaginoplasty

KEM.

n=41

Method:
Two approximately 6 cm wide by 8 cm long peritoneal flaps were raised from the anterior aspect of the rectum and the sigmoid colon, and the posterior aspect of the bladder to create the apex of the neovagina.

Results:
average followup 114 ± 79 days.
Vaginal depth and width were measured to be 14.2 ± 0.7 and 3.6 ± 0.2 cm, respectively. The peritoneal flap added an additional 5 cm of depth beyond the length of the skin graft.

Jacoby A et al. J Urol 201: 1175 (2019)

Transrectal ultrasound guided hydrodistension

KEM.

Aim of the study: to improve security while preparing the neovaginal channel

Technique: TRUS-guided perineal injection of 40-60ml normal saline between Denonvilliers‘ fascia and the anterior rectal wall to create a dissection of at least 20mm between these two layers

For better intraoperative visualization dying the hydrodissected space with 2ml of methylenblue

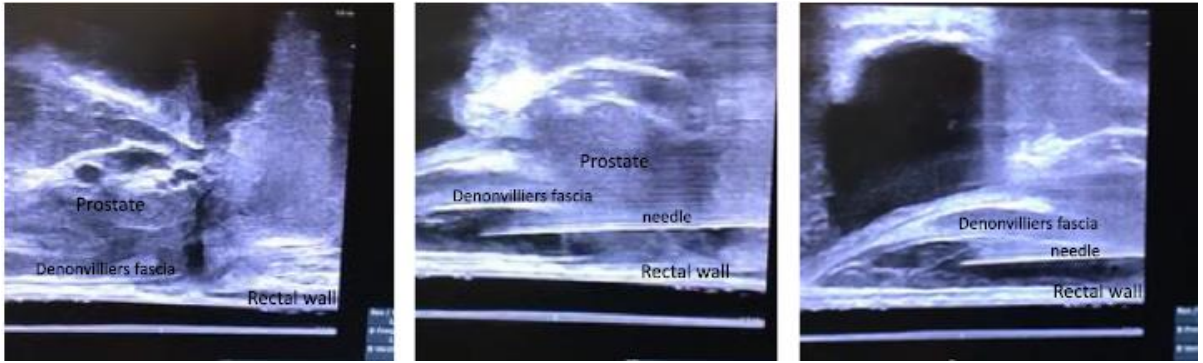

Panic A et al. J Sex Med 18:1134 (2021)

Transrectal ultrasound guided hydrodistension

n=54 with HST and n=84 controls

	vaginal depth (cm)	vaginal width (cm)	rectal injury (n)	OR-time (min)
HST	14,4	4,2	0	211
controls	13,5	3,8	2	218
p	0,01	<0,001	0,26	0,19

Panic A et al. J Sex Med 18:1134 (2021)

fistula-repair + laparoscopic neovagina formation by use of bowel - salvage surgery in case of rectovaginal fistula

KEM.

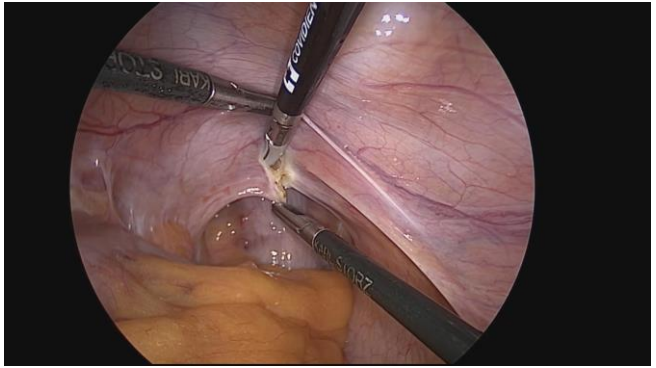

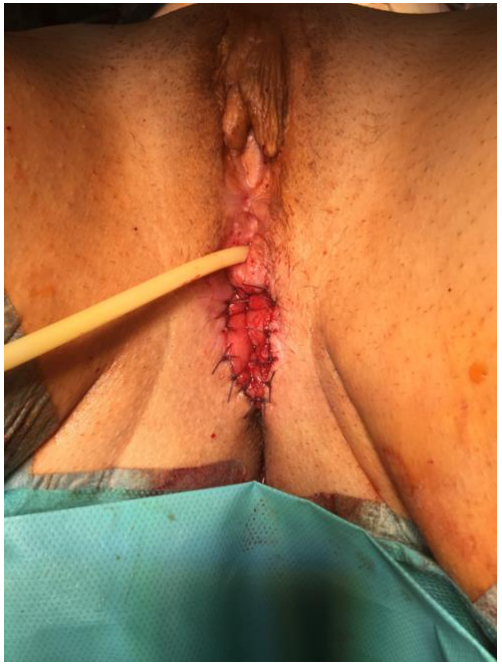

n = 8
rectovaginal fistula and consecutive vaginal atrophy;
closure of the fistula,
reconstruction of a sigma-neovagina (n=7) or an ileum-neovagina (n=1) after med. 16,5 months

Sacrocolpopexy for neovaginal prolapse

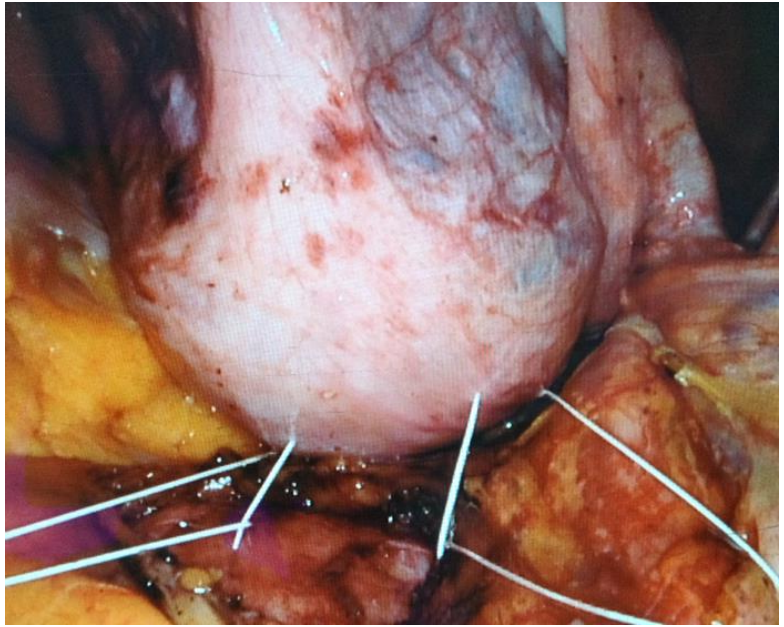

Risk of prostate cancer in transgender women

Reference	Age, y	Age at Start of Cross-sex Hormones, y	Presenting Symptom	PSA at Diagnosis (ng/mL)	Metastases Present?	Gleason Score	Mortality
Markland (1975)[6]	54	48	Unknown	Unknown	Unknown	Unknown	Unknown
Thurston (1994)[7]	64	52	LUTS	27	+	Unknown	+
van Haarst et al. (1998)[8]	63	53	Weight loss, bone pain	>100	+	Unknown	Clinically stable
Miksad et al. (2006)[9]	60	19	Hematuria	240	+	8	Clinically stable
Dorff et al (2007)[10]	78	52	Hematuria	177	+	9	Clinically stable
Molokwu et al. (2008)[11]	60	19	LUTS	Increased, no specific value	Unknown	Unknown	Unknown
Turo et al. (2013)[12]	75	45	LUTS	13.5	+	7	+
Ellent et al (2016)[13]	65	30	LUTS	19	+	9	Unknown
Sharif et al (2017)[14]	56	36	Unknown	5	-	7	Clinically stable

Deebel NA et al. Urology 110:166 (2017)

FtM-alignment: phalloplasty
lymphovenous anastomosis to prevent edema of the forearm

(figure by Berli JU et al. Plast Reconstr Surg 147: 801e (2021))

Preparation of a lymphatic vessel of the backhand, which is anastomosed to a subcutaneous vein at the skin left at the ulna

Personal communication by B. Safa Buncke Clinic, San Francisco

Implantation of the ZSI 475 FTM erectile device after phalloplasty

KEM.

3-piece inflatable erectile device



close-up of the realistic glans shape

close-up of the fixation plate

close-up of the testicle-shaped pump

Verla W et al. J Sex Med 18: 615 (2021)

Implantation of the ZSI 475 FTM erectile device after phalloplasty

KEM.

n=57

med. follow-up 16 (10-21) months

no intraoperative complications

postoperative complications: 18/57 (32%)

cylinder protrusion 1/57 (1,8%); infection 8/57 (14%); malpositioning 4/57 (7%); mechanical failure 4/57 (7%); urinary retention 1/57 (1,8%)

explanation rate 13/57 (23%)
explanation-free survival rate 84, 80 and 80% after 6, 12 and 18 months

Verla W et al. J Sex Med 18: 615 (2021)

Full facial feminization – all in one procedure

FFS envisages modifications of hard and soft tissues and is both reductive and augmentative



Raffaini M et al. J Craniofac Surg 2018

Full facial feminization – all in one procedure

reduction of the frontal sinus (most aggressive procedure, high risk of acute frontal sinusitis)
Thickness of the anterior wall of the frontal sinus – measured by a cone-beam maxillofascial CT scan and 3D reconstruction – was important for which procedure was chosen set-back or bone remodeling
Set-back 6mm and bone thickness 7-8mm, then all in one procedure
Set-back 5mm and bone thickness 3-4mm, then two stage procedure

Midface
Augmentations of variable grades of the zygoma, malar and check subunits using lipofiling

Lower face
Mandible represents a factor influencing the technique
Free of malocclusion or orthodontic correction, then all in one procedure
Malocclusion, then two stage procedure

Raffaini M et al. J Craniofac Surg 2018

Full facial feminization – all in one procedure

KEM.

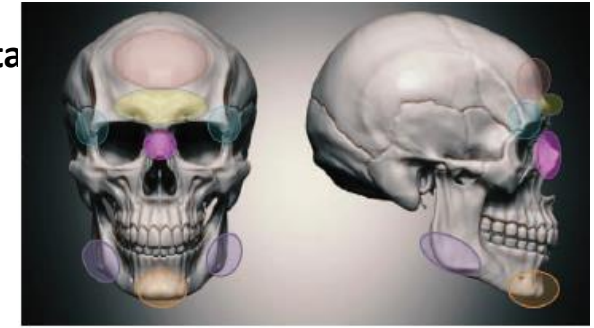

Upper face: reduction of the frontal sinus (most aggressive procedure, high risk of acute frontal sinusitis), reduction of the prominence of the orbita brow lifting, lateral canthopexy, correction of the hairline

Thickness of the anterior wall of the frontal sinus is important, for which procedure was chosen:
Set-back 6mm and bone thickness 7-8mm, then all in one procedure
Set-back 5mm and bone thickness 3-4mm, then two stage procedure

Midface: nose reshaping, malar/cheek subunite remodeling with lipofilling

Lower face: reduction of the squareness of the mandible through osteotomies and remodeling, removal of a wedge of the chin

Mandible represents a factor influencing the technique:
Free of malocclusion or orthodontic correction, then all in one procedure
Malocclusion, then two stage procedure

Raffaini M et al. J Craniofac Surg 2018

Full facial feminization – all in one procedure

Outcome assessment by 2 surgeons not involved in surgery (examination and photos) by the patients (aesthetic numeric analoge scale -ANA) (figure 8+9)

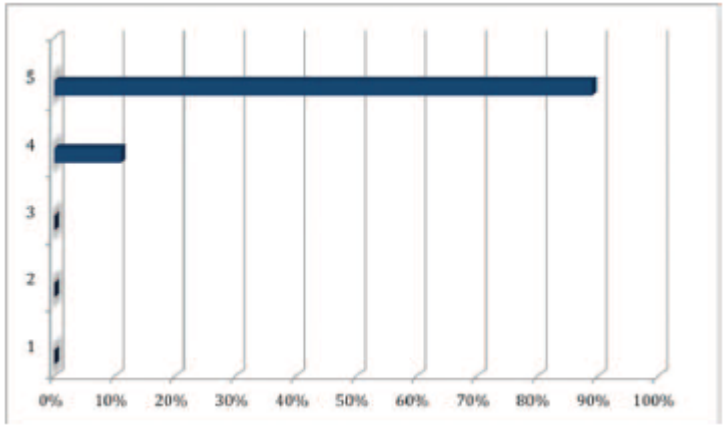

assessment by the surgeons

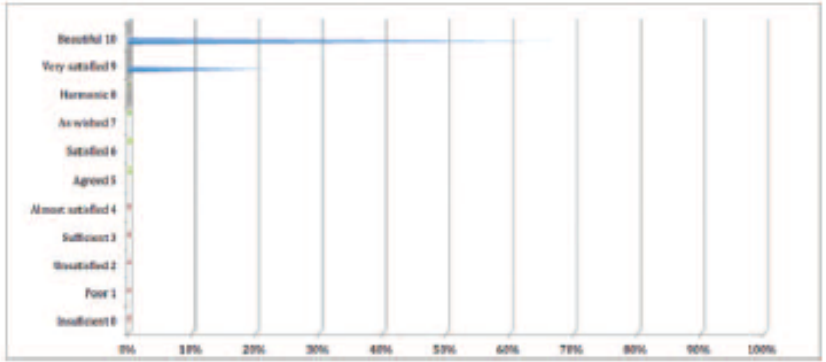

assessment by the patients

Raffaini M et al. J Craniofac Surg 2018

Full facial feminization – in 2 stages

2 stages seperated by 1 week interval

1. **stage with <u>upper face procedures</u>**
   forehead contouring, orbital shave, hairline advancement, blepharoplasty, rhinoplasty and cheek augmentation
2. **stage with <u>lower face procedures</u>**
   V-line jaw shave, chin reduction, Adam‘s apple shave, lip lift and neck lift

Advantages: reduced swelling of the upper face after one week – swelling reduces in a top-to-down manner due to gravity - , nose splint has been removed;
If rhinoplasty and jaw shave are done together, extubation becomes difficult as the nose is packed and also the jaw is tightly bandaged. Avoiding intraoral procedures during the first stage reduces infection rate

Telang PS Indian J Plast Surg 53: 244 (2020)

Prospective quality-of-life outcomes after FFS an international multicenter study

KEM.

A tool validated in the general facial aesthetic surgery was adapted for use in the transgender and gender-diverse population and underwent standard reliability validation.

Gender appearance and general asthetics were rated by reviewers and compared to cisgender women controls.

Photographs were independently rated by 32 cisgender and transgender raters.
Cephalometric values were determined.

Photogrammetric analysis of outcomes of FFS surgery pre- and </= 1 month postoperatively

	Preoperatively*	≤1 Mo Postoperatively*	p†
Forehead inclination, deg	70.0 ± 5.2	72.2 ± 5.9	0.0001
Glabellar angle, deg	101.7 ± 10.1	96 ± 8.7	<0.00001
Nasolabial angle, deg	97.7 ± 12.2	104.2 ± 15.2	<0.00001
Frankfort horizontal–mandibular angle, deg	21.4 ± 5.1	22.7 ± 4.5	0.0034
Nasofrontal angle, deg	131.8 ± 11.1	139.5 ± 10.0	<0.00001

Morrison SD et al. Plast Reconstr Surg 145: 1499 (2020)

Prospective quality-of-life outcomes after FFS an international multicenter study

KEM.

Photogrammetric analysis of outcomes of FFS surgery pre- and > 6 months postoperatively

	Preoperatively*	≥6 Mo Postoperatively*	p†
Forehead inclination, deg	71.1 ± 4.9	73.7 ± 5.1	<0.0001
Glabellar angle, deg	100.6 ± 8.6	95.8 ± 9.4	0.03
Nasolabial angle, deg	98.7 ± 13.0	100.9 ± 11.6	0.049
Frankfort horizontal–mandibular angle, deg	22.6 ± 5.3	23.9 ± 5.1	0.01
Nasofrontal angle, deg	132.7 ± 11.0	139.8 ± 8.9	<0.00001

Patients had feminine gender appearance and good overall asthetic outcome, however these aspects were still not equal to those of cisgender women controls

Factors associated with less favorable outcome were age and smoking, but not particular areas of the face or number of procedures

Morrison SD et al. Plast Reconstr Surg 145: 1499 (2020)

Perception of patient gender

KEM.

Aim of the study: to determine, if FFS changes the perceived gender of patients in the public eye

Online survey platform with control photographs (frontal and lateral) of cis-gender males and females as well as preoperative and postoperative FFS patients



Fisher M et al. Aesth Surg J 40: 703 (2020)

Perception of patient gender

Cis-gender males and females were gendered correctly in 99%.

Preoperative FFS patients were gendered as female in 57%, while the percentage in postoperative FFS patients increased to 94%

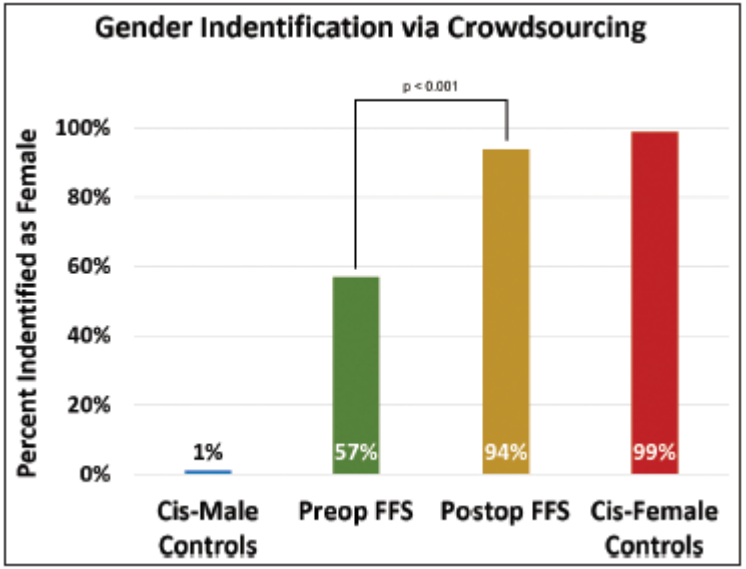

Fisher M et al. Aesth Surg J 40: 703 (2020)

Facial recognition neural networks

KEM.

Aim of the study: to study the effectiveness of FFS by investigating pre- and postoperative gender-typing using facial recognition neural networks

Photographs of controls and FFS patients were processed through 4 convolutional neural networks (Microsoft, IBM, Amazon and Face++)

Cis-gender males and females were correctly in 100 and 98%; preoperative FFS patients in 53% and postoperative FFS patients in 98%

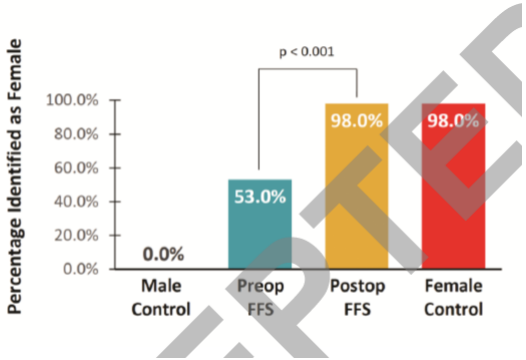

Chen K et al. Plastic and reconstructive surgery J (2019)

Modification of the hands

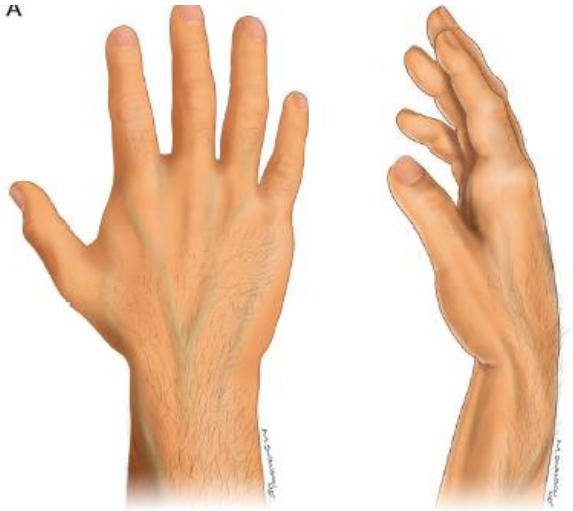

ideal masculine hand

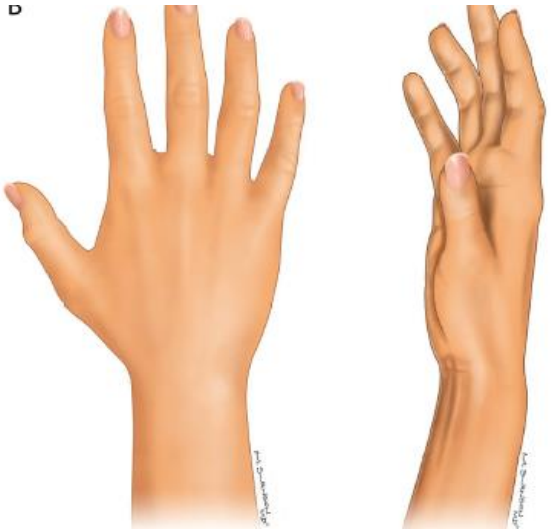

ideal feminine hand

Modification of the hands

KEM.

There is no current surgical approach for masculinization of the hands.
Surgical techniques of feminization are the same as those for hand rejuvenation

<u>Fat grafting/lipomodeling</u> of the dorsal hand, which decreases the visibility of tendons and vasculature

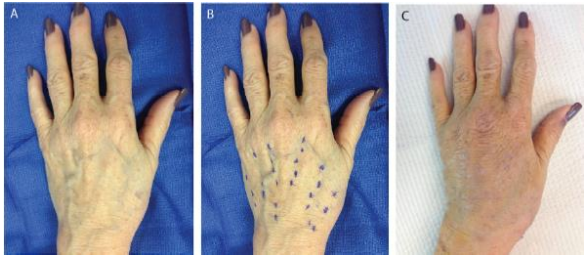

Injection of the fat only into the superficial layer, or both the superficial and the depp layer, 15-30ml fat is transferred
Fat grafting can also be used for modelage of other parts of the hands, injection into the fingers increases the risk of neuropraxia.
Manipulation of digit length is excessively morbid with significant risks to the function of the hand

Complication rate 0-11% (hematoma, edema, paresthesia, ecchymosis, fat absorption)
patients‘ satisfaction 82-100%

Lee et al. Aesth Plast Surg 45: 589 (2021)

Modification of the hands

Hand lift to decrease wrinkles
Excision of dorsal hand and wrist skin with minimal undermining
Risks: Injury of the branches of the radial and ulnar nerve, wound dehiscence, decreased range of motion of the wrist

Vein removal
Use of endovascular laser ablation to remove visible dorsal veins
Complications: edema, ecchymosis, pain

Arthrodesis to aim at a more slender hand by decreasing the prominence of DIP and PIP joints as well as the carpometacarpal joint

Manipulation of digit length excessively morbid with significant risks to the function of the hand

Lee et al. Aesth Plast Surg 45: 589 (2021)

Modification of the hands

Nonsurgical techniques:

Injectable fillers (porcine collagen, hyaluronic acid calcium hydroxylapatite, poly-1-lactic acid, allograft matrices) – most commonly used for the face – for this indication off lable as an alternative for fat grafting

because fillers are short term agents,

therefore repeat procedures are necessary

Complication rate 0-85% (foreign body granulomas)

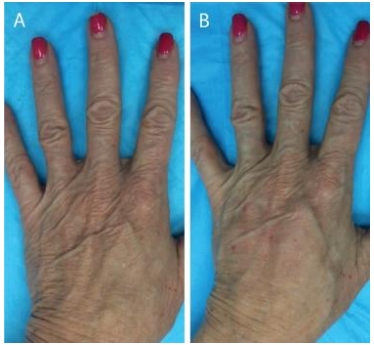

Sclerotherapy

as an alternative for vein removal

Injection of 0,25-1% sodium tetradecyl sulfate or 1-3% polidocanolis mixed with room air or carbon dioxide gas

Lee et al. Aesth Plast Surg 45: 589 (2021)

Guideline in progress
Gender incongruence and –dysphoria during childhood and adolesence: diagnostics and treatment

Measurement of psychosocial resources and QoL

KEM.

n=158; group1: GAS 0,3- 3 years ago, n=48
group2: GAS 3,1-10 years ago, n=62
group3: GAS 10,1-21 years ago, n=41

Material: Essen Resource Inventory (ERI)
Sense of Coherence Scale
Social Support Scale

Short Form Health Survey

Time points of measurement: 3 years and 4 weeks ago

Breidenstein A et al. J Sex Med 16:1672 (2019)

Measurement of psychosocial resources and QoL

KEM.

ERI with 3 dimensions of psychosocial resources to strengthen person‘s resilience:
personal/PER (character traits, abilities that originate in individual‘s personality)
social/SOR (social relationships with stress-buffering effects)
structural/STR (person‘s supporting environment, residential situation, financial security)

SOC: person‘s ability to flexibly react to life changes
SSS

ERI shiwed significant increase in all 3 dimensions and ERI global score from 3 years to 4 weeks for group 1, no differences for group 2 and 3
ERI 4 week score were similar for all 3 groups, while ERI 3 year score was higher for group 2 and 3 compared with group 1

SOC: significant group effect, although no significant group differences
SSS: no group differences for physical aspects, but for mental aspects

Breidenstein A et al. J Sex Med 16:1672 (2019)

Measurement of psychosocial resources and QoL

KEM.

Compared with controls trans women showed significant lower scores on all ERI dimensions.
no differences in SOC and SSS
no group differences in physical QoL, but in mental QoL, which was significantly lower compared to controls.

Breidenstein A et al. J Sex Med 16:1672 (2019)